# Classification of Lesions in Subcutaneous Tumor Models in Mice

*Melania Osto, Julie Parchet, Andrina Zbinden, Ahmet Varol, Birte Appelt*

This poster classifies lesions in subcutaneous tumor models, with images to aid identification and determination of humane endpoints through visual assessment.

Ulceration is generally a humane endpoint; exceptions may be granted case-by-case in the Application for a License to Perform Animal Experiments (Form A).

**Normal**

No ulceration.

The skin overlying the subcutaneous tumor is bulging but remains intact.

**Necrosis:** ***refers to cell death in the skin layers overlying the tumor***

a) Shiny skin that appears unusually glossy or reflective, hypervascularized. Skin is under stress;

b) Taut skin may feel stretched or tight, tightness is typically a result of fluid accumulation/edema beneath the skin, which can occur as a response to a growing tumor;

c-d) Discolored skin with redness, darkening, or a purplish hue, indicating skin susceptible to breakdown, potentially leading to ulceration. Ulcer has not yet developed at this stage.

**Excoriation:** ***topical, encrusted, dry skin lesion***

e) Erosion of the skin overlying the tumor with replacement by a scab (or fibrin crust).

**Ulcer:** ***loss of epidermis and, at least, the superficial portion of the dermis***

f) Pitted/cratered ulceration with crust;

g) Wet open wound.

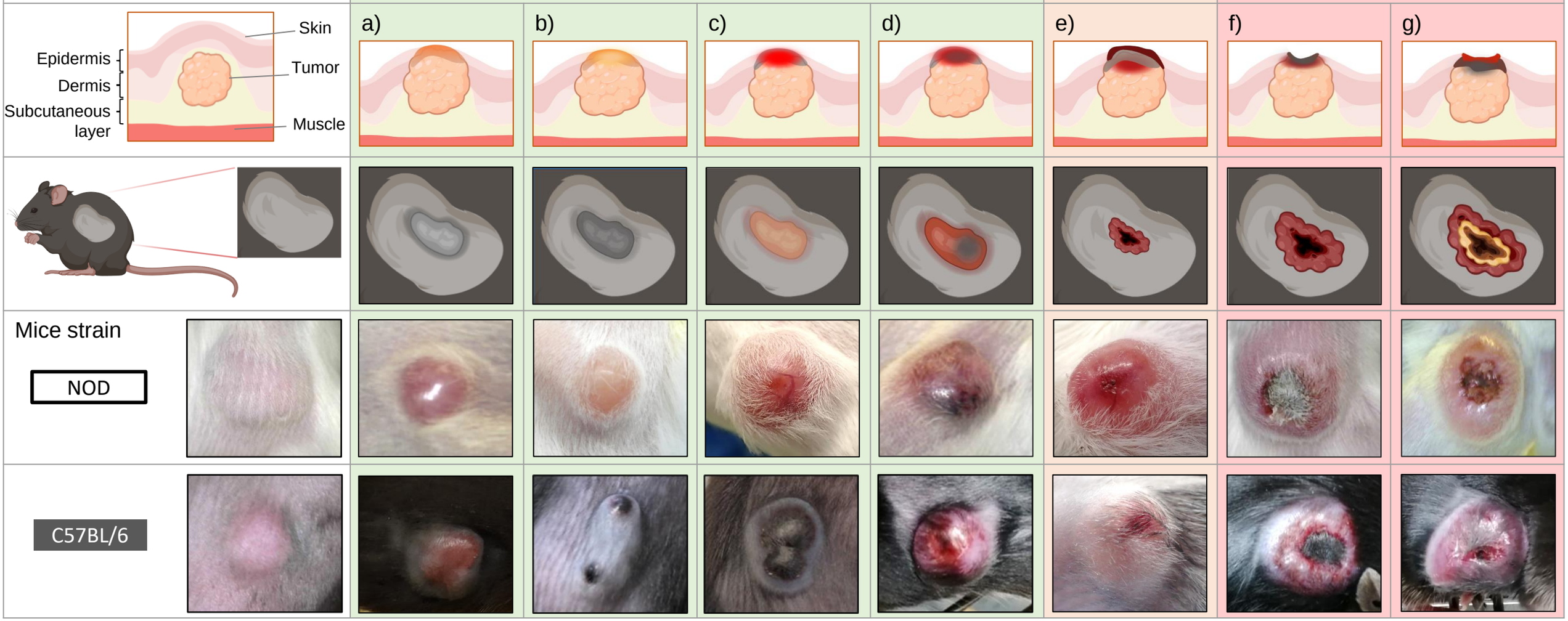


*The images shown are for illustrative purposes only and do not necessarily represent the results of animal experiments carried out in Switzerland.*

*illustrations created with BioRender.com*